

بِسْمِ اللَّهِ الرَّحْمَنِ الرَّحِيمِ

# **Retinal Detachment Repair in Traumatic Iris Loss**

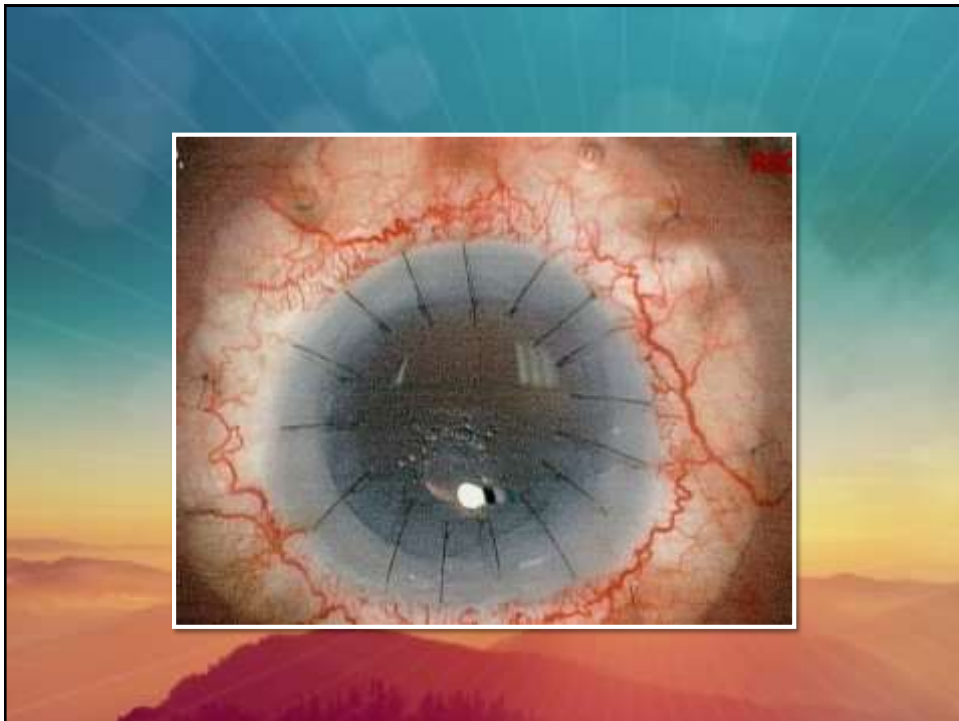
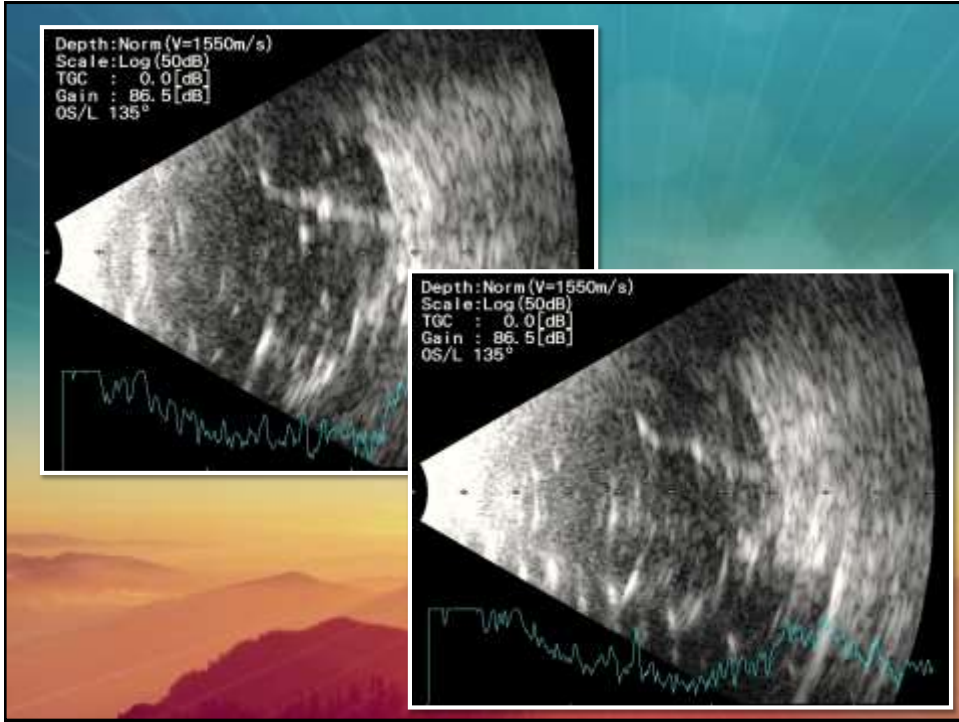
**Dr. Mamdouh Kabeel, MD**

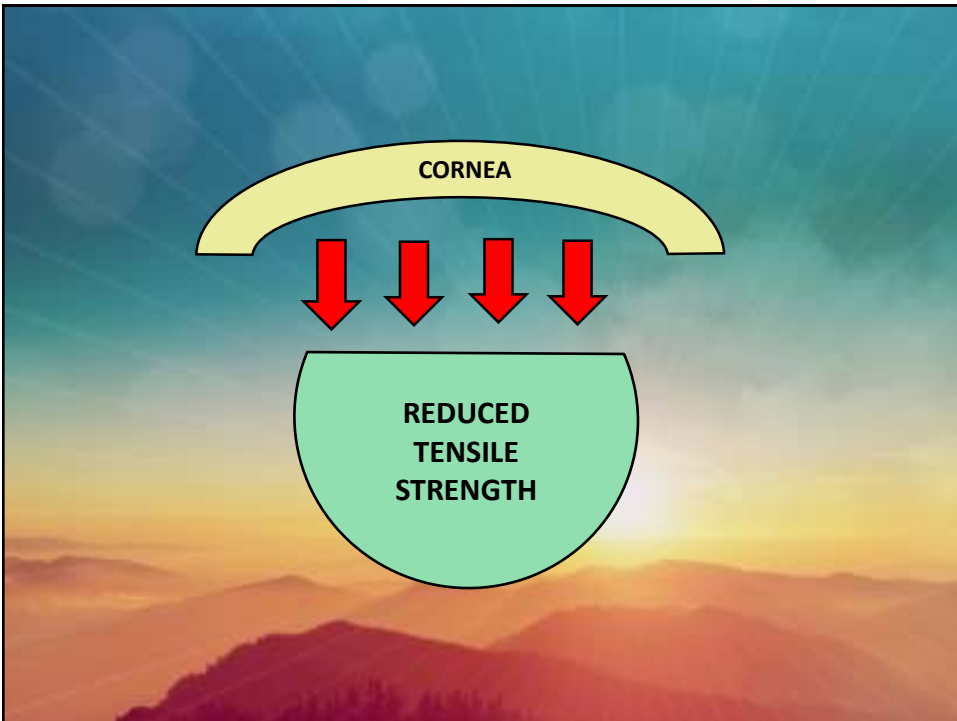
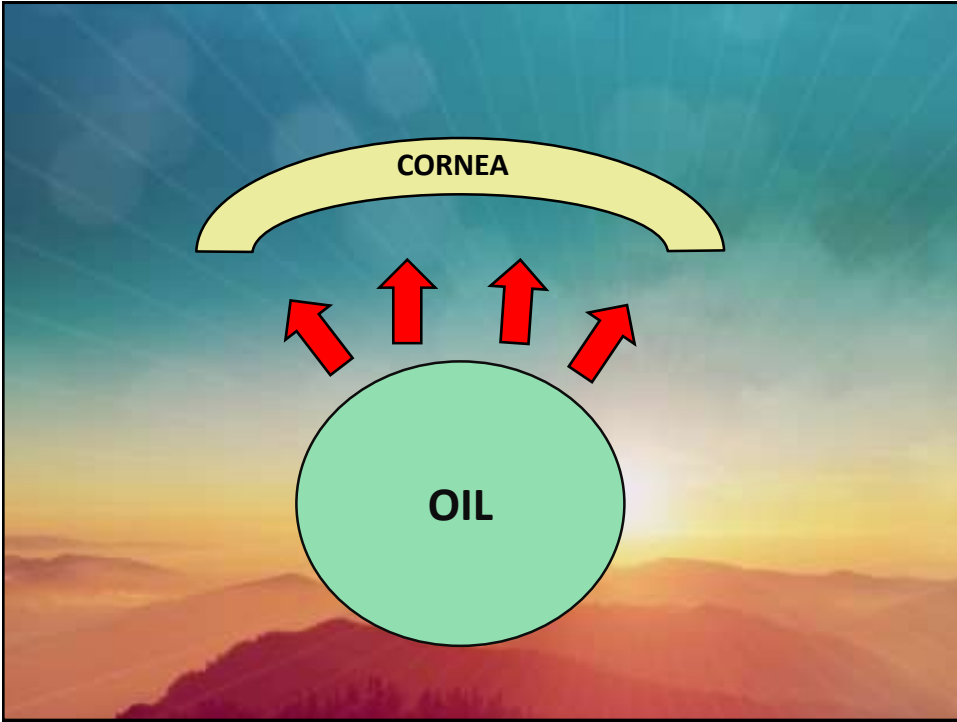
## 1<sup>ST</sup> PRESENTATION ; 29<sup>TH</sup> April 2015

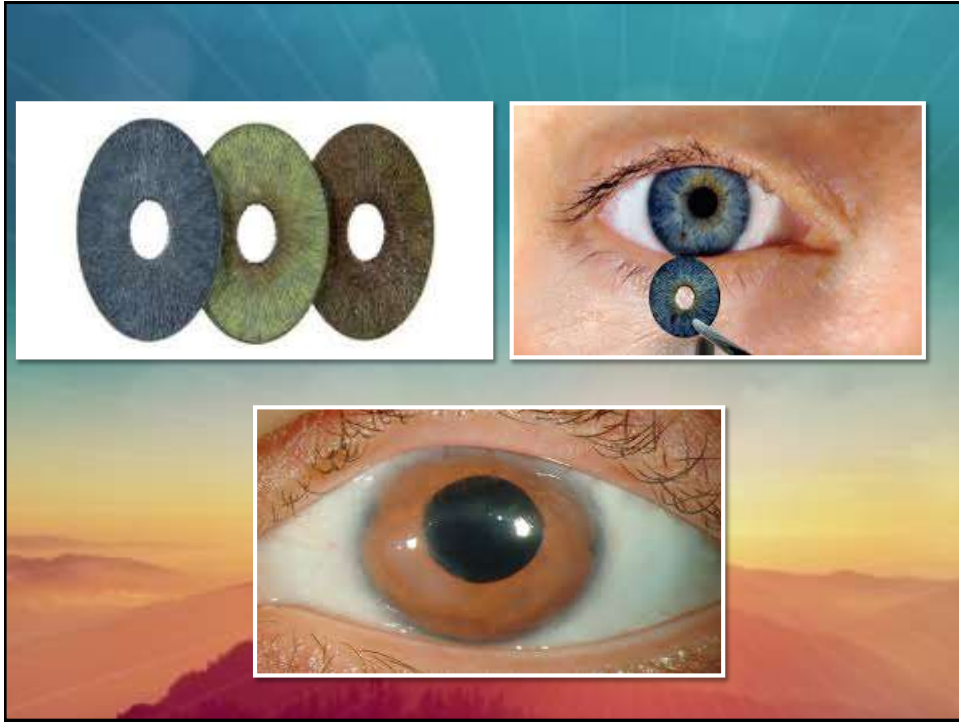
- 36 y/o male
- ↓↓ VA to LP; OS
- Chemical Trauma, 1 month
- O/E revealed: Total anterior Staphyloma
- No details could be detected anteriorly
- U/Z revealed completely normal Posterior Segment
- No recommended interference at the moment
- Anti-Glaucoma meds + Surface lubricant + F/U.

## 2<sup>nd</sup> Presentation : 7 mos. Later

- **He did Anterior Segment Reconstruction in 2 stages (outside Magrabi)**
  - Corneo-scleral graft : 6 mos. ago and Repair of RD
  - Keratoplasty **2 days** ago with removal of oil
- **O/E:**
  - clear corneal graft :
  - Residual oil in AC
  - No iris
  - Aphakia
  - Recurrent RD with Residual oil
  - V/A is HM
- **I prefer to wait for 1 more week**

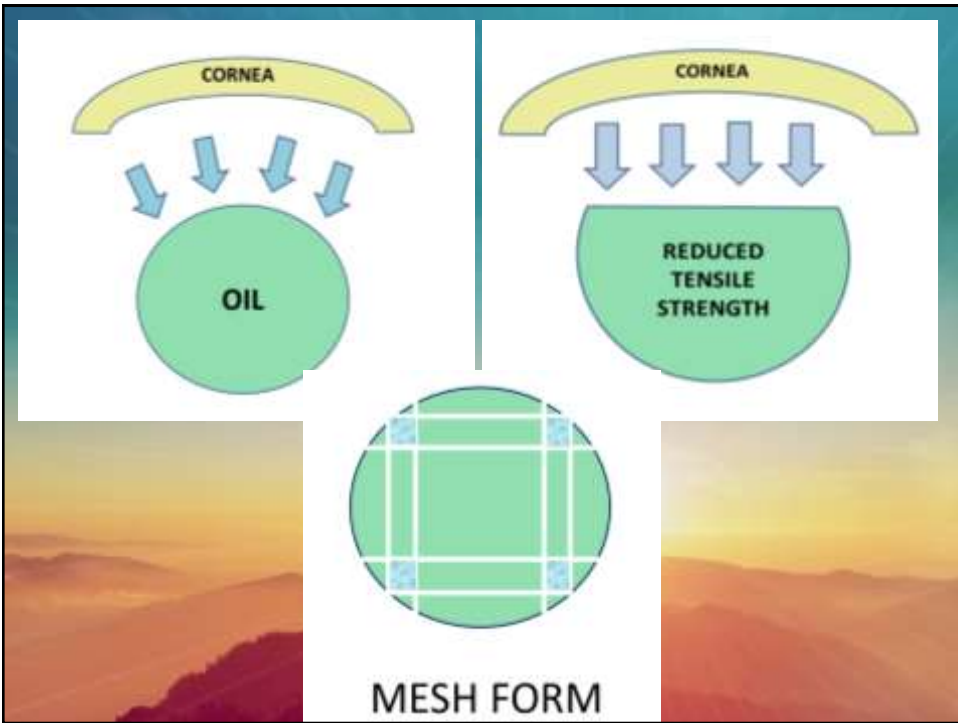
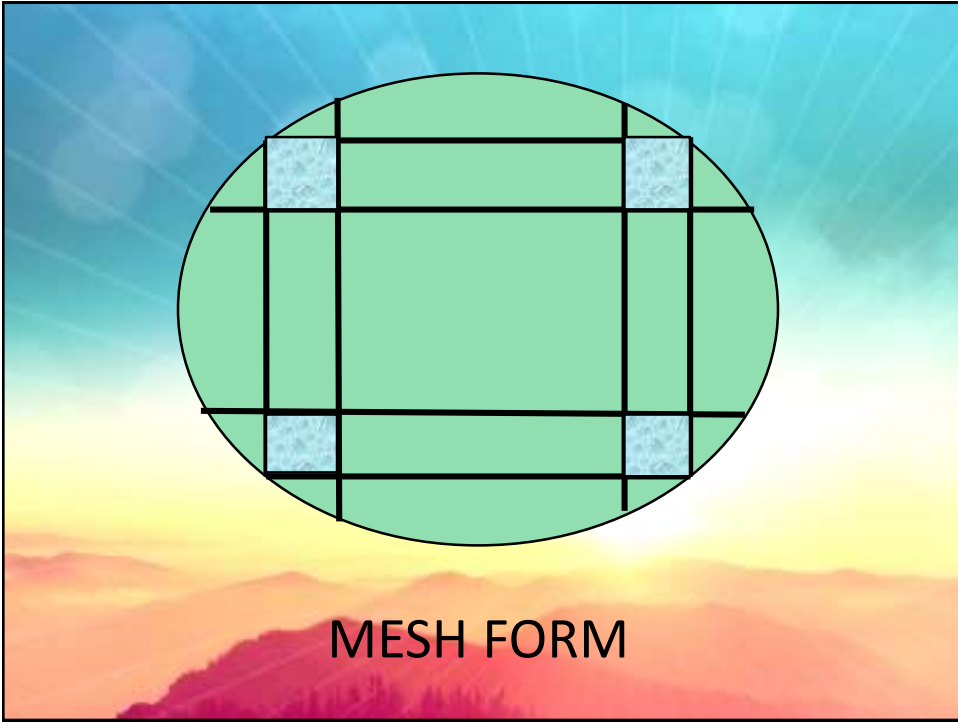


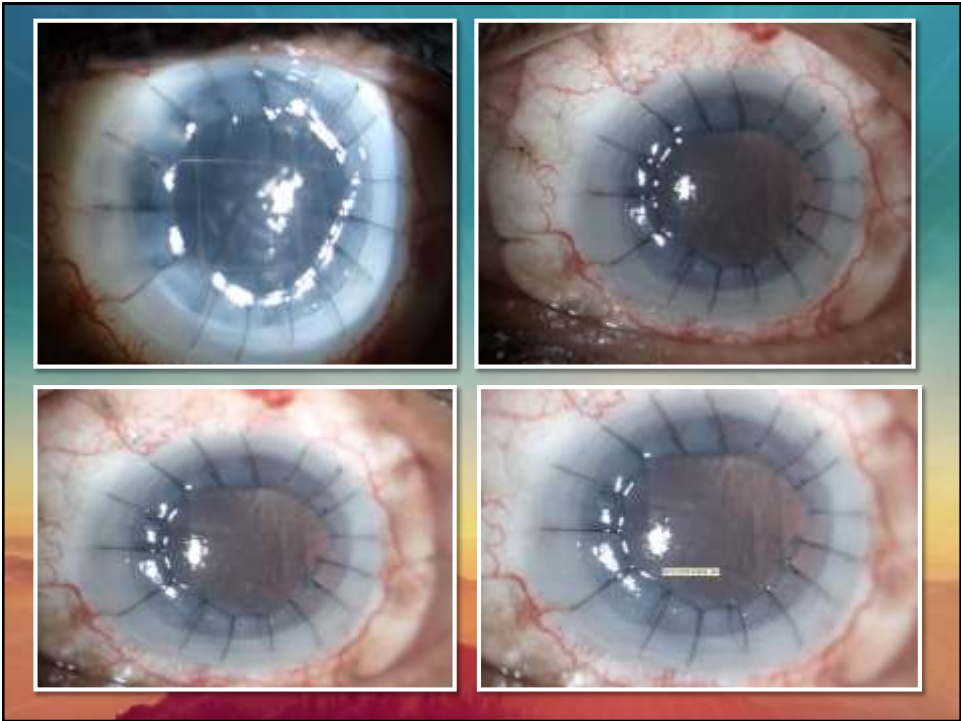
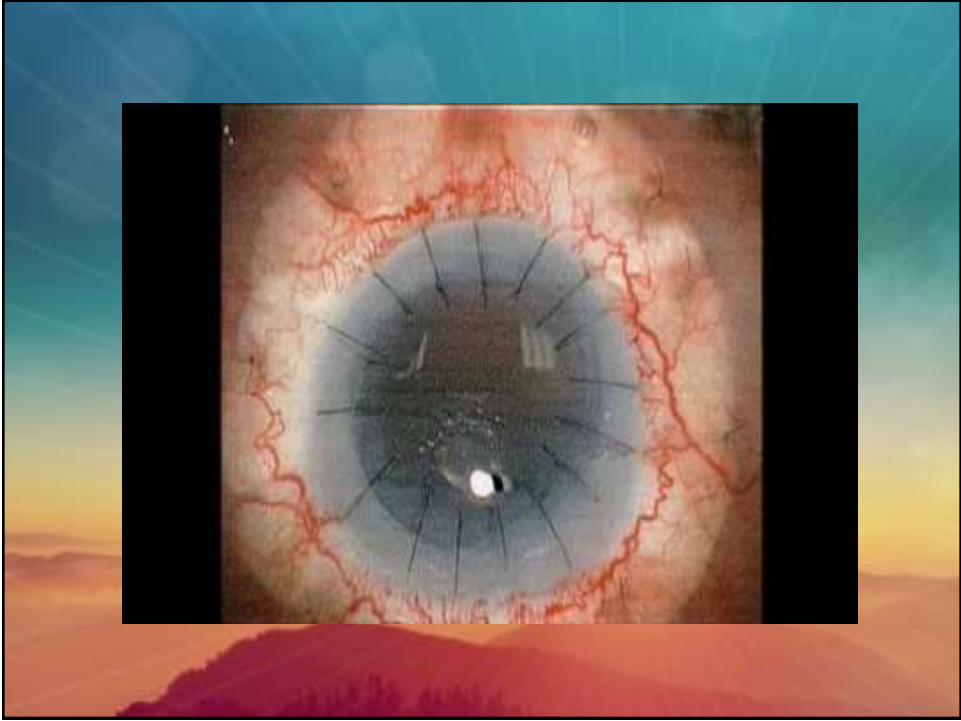


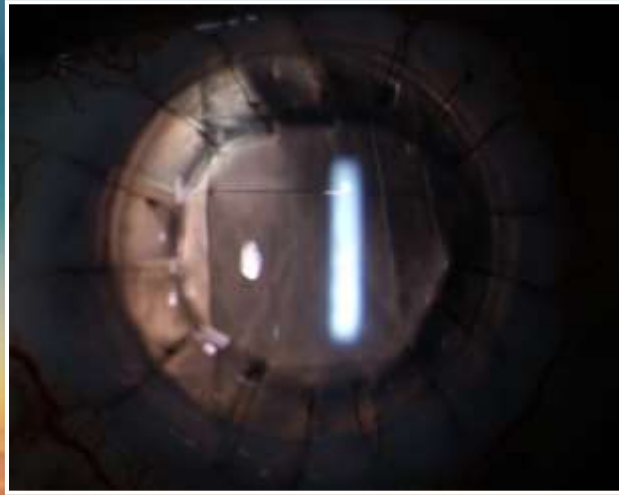


- In traumatic
- Congenital aniridia
- Iris coloboma









1 month after sx  
BCVA 20/400

