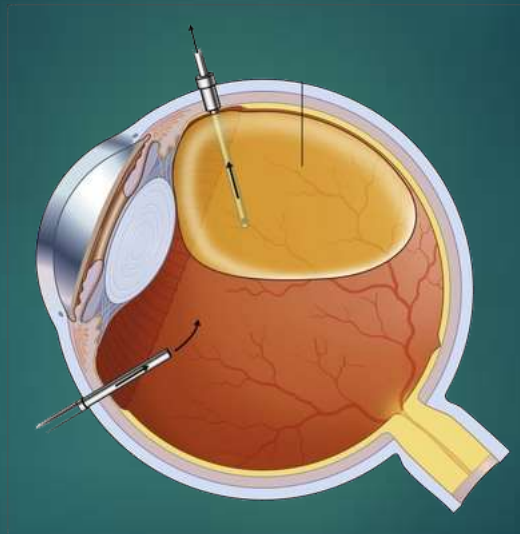


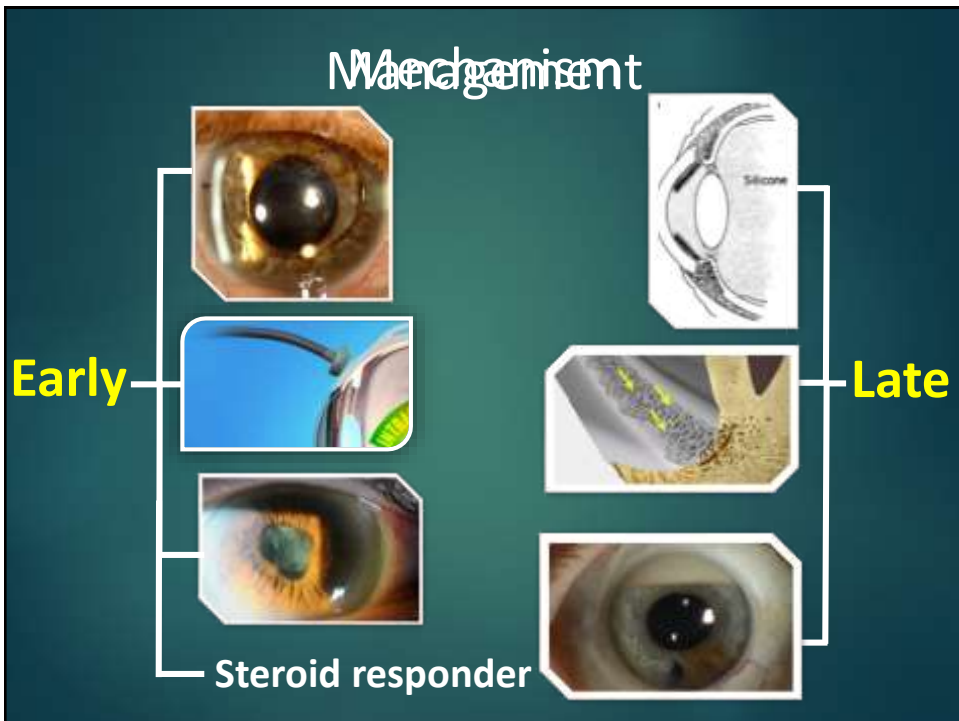
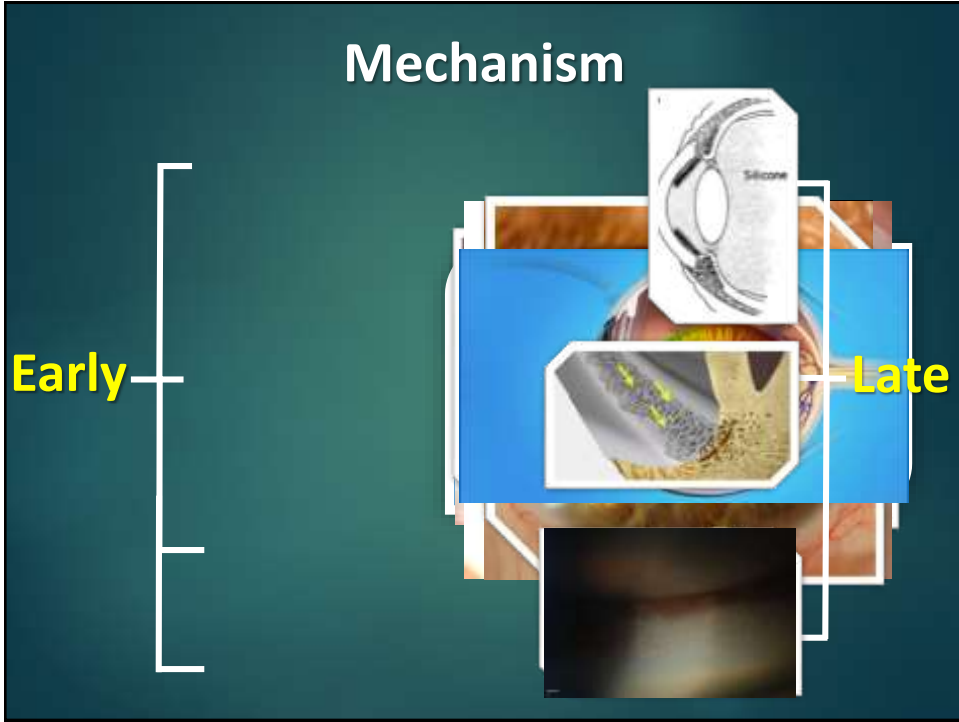


Silicone Oil Induced Glaucoma

Sherif Bayoumi


Ophthalmology Specialist
Magrabi Hospitals and Centers
FICO, MRCSEd





Management

Early



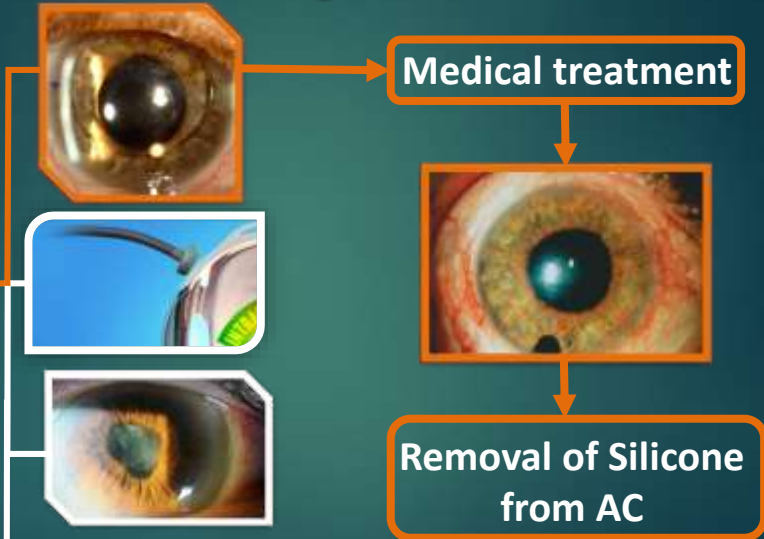
• Medical treatment
Avoid Prostaglandins

Steroid responder

This slide illustrates the management of an eye condition. It features three images of an eye: the top one is cloudy, the middle one shows a surgical procedure, and the bottom one is clear. A bracket on the left groups these images under the word 'Early'. To the right, a bullet point indicates 'Medical treatment' with the instruction 'Avoid Prostaglandins' in yellow. At the bottom, the text 'Steroid responder' is connected to the images by a line.

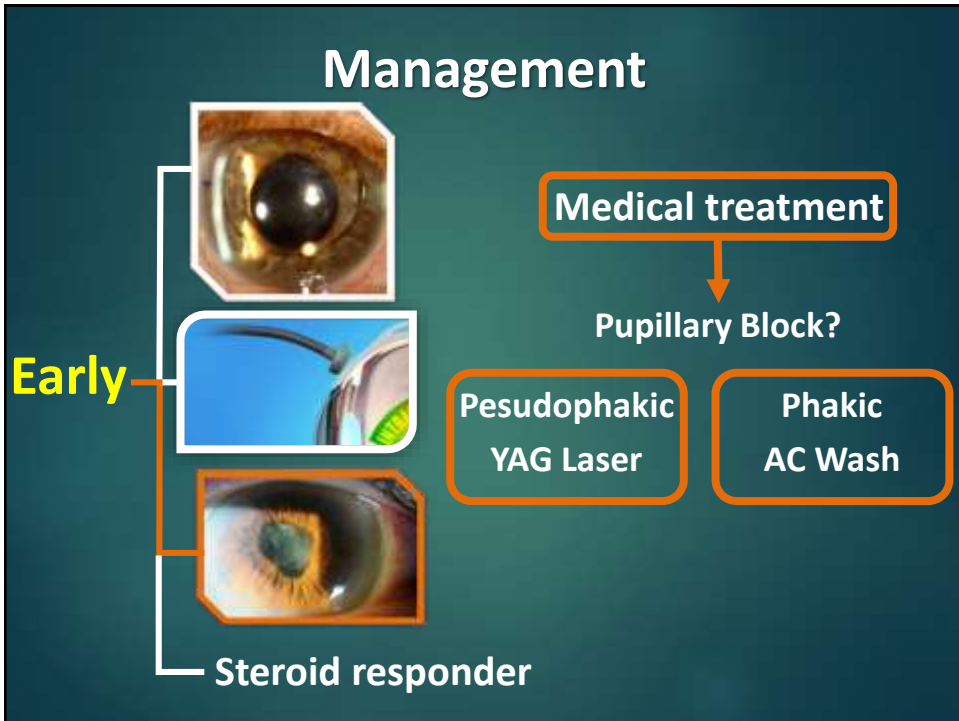
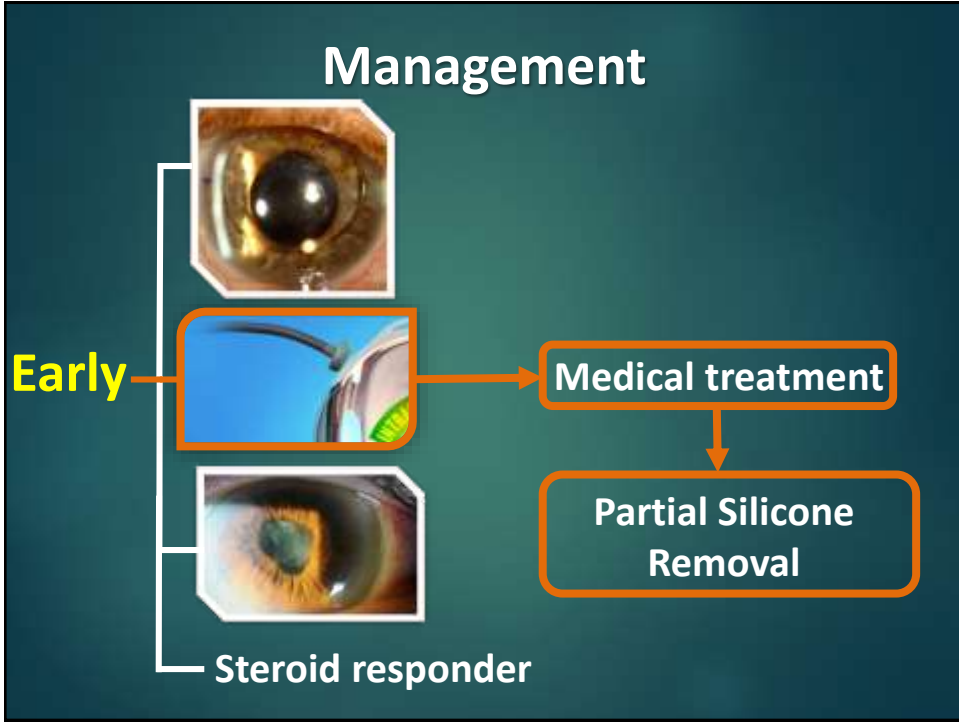
Management

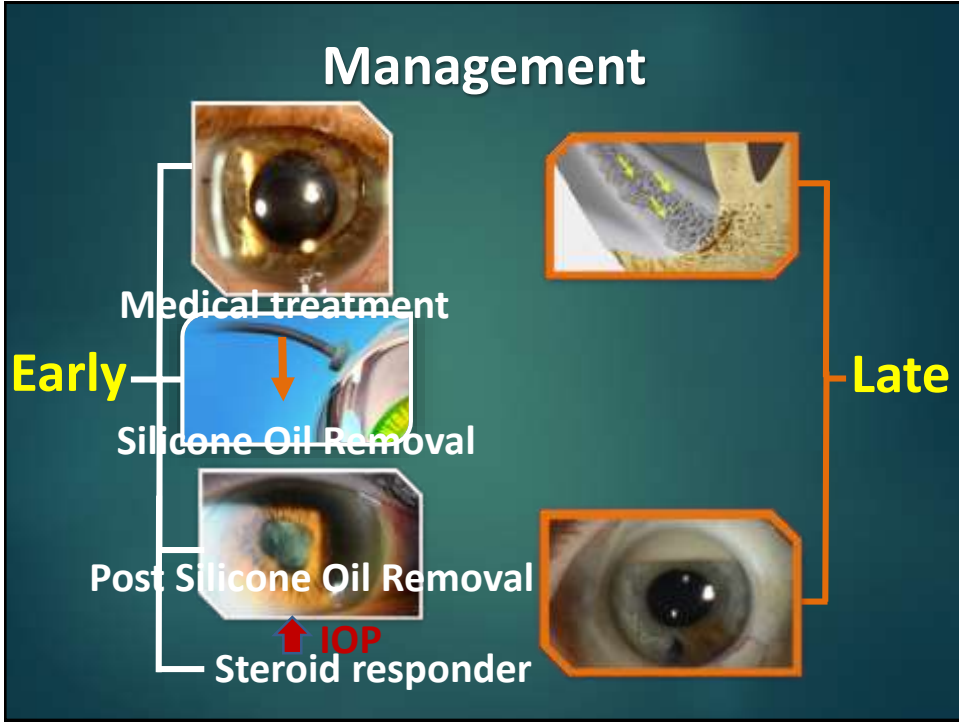
Early



Steroid responder

This slide shows a management flowchart. It starts with three eye images (cloudy, surgical, clear) on the left, grouped under 'Early' and labeled 'Steroid responder'. An arrow points from the top image to a box labeled 'Medical treatment'. A second arrow points down to another eye image showing a cloudy eye with a dark spot. A final arrow points down to a box labeled 'Removal of Silicone from AC'.





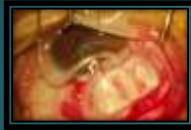Surgical Treatment

Surgical Treatment

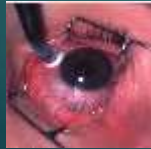- Filtration Surgeries



- Drainage Devices



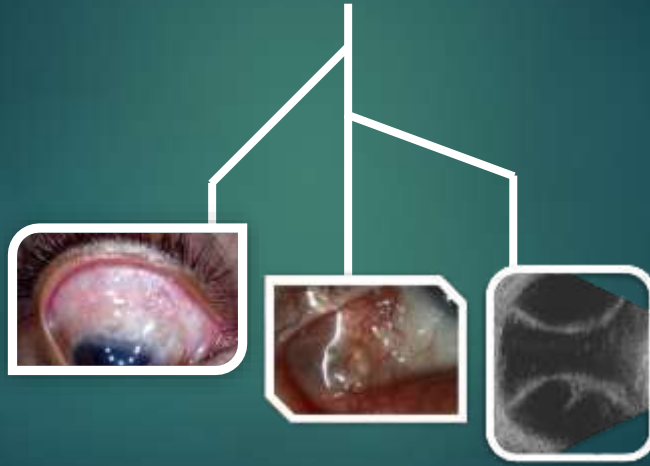
- Cyclodestructive



Is it that simple?

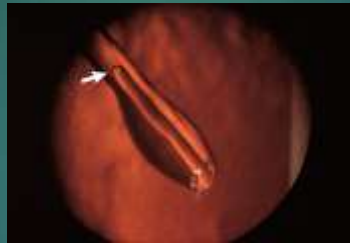
Surgical Challenges

Filtration Surgeries



Surgical Challenges

Drainage Devices



Management

Cyclodestructive Procedures

- All other surgical options failed or not possible
- Poor visual potential
- High risk of visual loss

Take home message

Understanding the pathogenesis, timely diagnosis and management helps saving vision.

Proper techniques during retinal surgery will reduce complications rates and promotes a higher success rate of any further surgery needed.

Thank You